Detection of Right to Left Shunts in Decompression Sickness in Divers

Edmund K. Kerut, MD, Walter D. Truax, MD, Thor E. Borreson, MD, Keith W. Van Meter, MD, Michael B. Given, PhD, and Thomas D. Giles, MD

Decompression sickness (DS) represents a significant risk for underwater divers and may cause severe neurologic damage.[1] It has long been suspected that venous gas emboli generated by the release of nitrogen from peripheral tissues during decompression may account for neurologic complications among divers suffering from DS. Because the lungs filter venous gas emboli, it has been proposed that a patent foramen ovale (PFO) may be 1 mechanism by which sufficient numbers of venous emboli enter the arterial circulation. We hypothesized that transcranial Doppler with saline bubble contrast would detect only clinically meaningful PFOs and thus be superior to transthoracic (TTE) and transesophageal echocardiography (TEE) for predicting divers' risk for DS.[2,3] To test our hypothesis, we conducted a comparison of the ability of TTE and TEE to detect a PFO with that of transcranial Doppler using saline bubble contrast in control subjects and divers referred for evaluation of DS.

• • •

Twenty-six divers referred for evaluation of DS and 30 nondiving control subjects who had no history of arterial embolism or cardiovascular disease agreed to be evaluated for the presence of a PFO. The protocol for shunt detection was approved by the Institutional Committee on the Use of Humans in Research, and each subject signed an appropriate consent form. Following clinical assessment, which included a full neurologic examination by a neurologist with expertise in diving medicine, the divers in the study were classified as follows: *possible* DS (transient nonspecific neurologic symptoms and a normal neurologic examination within 48 hours of surfacing); those with *probable* DS (significant neurologic dysfunction but with a normal neurologic examination within 48 hours); and those with *definite* DS (significant neurologic dysfunction and an abnormal neurologic examination, including motor weakness or ataxia).[4–6]

All subjects fasted for at least 8 hours before the study began. An 18-gauge catheter was placed in the right antecubital or hand vein for injection of 6 to 8 ml of agitated saline as previously described.[7] Studies were recorded with a Toshiba model 160 echocardiograph (Toshiba America Medical Systems, Tustin, California) utilizing a 2.5-MHz TTE transducer and a 5-MHz TEE probe. All imaging recorded from the TEE probe was in the transverse plane.

TTE and TEE studies were stored on high-fidelity half-inch videotape. Transcranial Doppler studies were recorded using a 2-MHz Doppler transducer (Edenmedizinische Elektronik-TC2000, Uberlinger, Germany) and stored digitally on a computer disk.

Simultaneous TTEs in the apical 4-chamber view with transcranial Doppler of the right middle cerebral artery were recorded. Agitated saline was injected twice during normal resting respiration, followed by 5 injections in conjunction with a Valsalva maneuver. The patient then received a light intravenous sedative, if desired, and the posterior pharynx was topically anesthetized. TEE probe intubation was performed, with the probe positioned for optimal imaging of the interatrial septum. Simultaneous transcranial Doppler of the right middle cerebral artery was recorded. The protocol for injections of agitated saline was identical to that described for TTE imaging.

TTEs were assessed as positive if any bubbles appeared in the left atrium or left ventricle after any of the 7 injections. A TEE was positive if contrast appeared in the left atrium during any of the 2 resting injections, or if contrast appeared in the left atrium after 2 of the 5 injections during the Valsalva maneuver. Three or more bubbles in the left atrium were necessary to classify an injection as positive. A TEE was considered "strongly positive" if >5 bubbles were seen in a single video frame for any injection. For all injections, contrast had to appear in the left atrium within 3 cardiac cycles of appearing in the right atrium in order to qualify as a PFO.

The sensitivity, specificity, and predictive value of the 3 modes of right to left shunt detection were determined as previously described.[8] The prevalence of DS was assumed to be ≤1%[9,10] among divers and was therefore ignored in calculations involving con-

TABLE I Right to Left Shunting During the Valsalva Maneuver

	Control Subjects (n = 30)	Probable + Definite DS (n = 15)	All Divers (n = 26)
Positive studies			
TTE	5 (17%)	3 (20%)	8 (31%)
TEE	14 (47%)	9 (60%)	15 (58%)
TD	7 (23%)*	7 (47%)	13* (50%)*

* p = 0.05 versus control.
DS = decompression sickness; TD = transcranial Doppler; TEE = transesophageal echocardiography; TTE = transthoracic echocardiography.

From the Cardiovascular Research Laboratory, Section of Cardiology, Department of Medicine, Louisiana State University Medical Center, New Orleans; Heart Clinic of Louisiana, Marrero; Culicchia Neurologic Research Foundation, Marrero; and the Section of Emergency Medicine, Department of Medicine, Louisiana State University Medical Center, New Orleans, Louisiana. Dr. Giles's address is: Louisiana State University Medical Center, Room 331E, 1542 Tulane Avenue, New Orleans, Louisiana 70112. Manuscript received March 25, 1996; revised manuscript received and accepted August 19, 1996.

0002-9149/97/$17.00
PII S0002-9149(96)00768-0

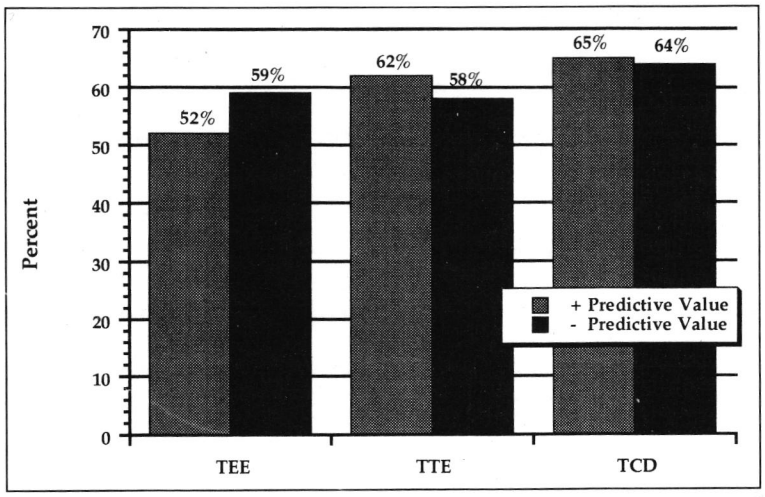

FIGURE 1. Positive and negative predictive values for detection of right to left shunts in divers with decompression sickness. TCD = transcranial Doppler; TEE = transesophageal echocardiography; TTE = transthoracic echocardiography.

trol subjects. Controls and all divers were compared using a nonparametric test for significance of difference between 2 proportions.[11]

The age of the controls (28.5 ± 5.6 years) and divers (29.1 ± 6.4 years) were similar; there were 3 women in each group. Contrast studies utilizing TTE, TEE, and transcranial Doppler during normal respiration revealed similar incidences of right to left shunting in all divers and control subjects. However, when the Valsalva maneuver was performed, the differences in right to left shunting became apparent (Table I). Importantly, all control subjects and divers who had a positive transcranial Doppler study had a "strongly positive" TEE. Also, a "strongly positive" TEE was invariably positive by transcranial Doppler. Transcranial Doppler was the only technique that statistically distinguished between the control and the "all divers" group ($p \leq 0.05$). Positive and negative predictive values for each echo-Doppler modality are shown in Table I.

• • •

This study suggests that intravenous bubble contrast injections performed during the Valsalva maneuver using transcranial Doppler may be superior to TTE and TEE for detection of clinically significant PFOs. As expected, TEE was the most sensitive technique for PFO detection in both the control group and the divers. It is likely that transcranial Doppler identified only larger right to left shunts, as demonstrated by the fact that only a strongly positive TEE had a positive transcranial Doppler. This could account for the higher positive and negative predictive values found for transcranial Doppler and the statistically significant difference in detection between controls and all divers.

In a prior study using TTE only, shunting occurred in 25 of 61 divers with DS (41%). TTE had a positive predictive value of 63%, and a negative predictive value of 57%. In a subgroup of 53 divers with neurologic injury, 23 (43%) had evidence of shunting. This group's positive predictive value was 61%, and the negative predictive value 62%. These divers were similar to a control group of 63 divers with no history of DS, having shunts in 15 (24%).[12]

Although the reported autopsy incidence of a probe patent PFO is approximately 27%,[13] with TEE we detected a PFO in 47% of control subjects. Using TEE, others investigators have reported a PFO prevalence of 38%[14] and 43%[3] in their control groups. Shunting of contrast bubbles may occur through PFOs that are too tight to allow passage of a probe.

In conclusion, transcranial Doppler may be better than TTE and TEE for detection of a clinically significant PFO in DS. Transcranial Doppler appears to detect only larger shunts compared with TEE.

1. Elliott DH, Kindwall EP. Manifestations of the decompression disorders. In: Bennett PB, Elliott DH, eds. The Physiology and Medicine of Diving and Compressed Air Work. 2nd ed. London: Baillier Tindall, 1982:461–472.

2. Di Tullio M, Sacco RL, Venketasubramanian N, Sherman D, Mohr JP, Homma S. Comparison of diagnostic techniques for the detection of a patent foramen ovale in stroke patients. *Stroke* 1993;24:1020–1024.

3. Job FP, Ringelstein EB, Grafen Y, Flachskampf FA, Doherty C, Stockmanns A, Hanrath P. Comparison of transcranial contrast Doppler sonography and transesophageal contrast echocardiography for the detection of patent foramen ovale in young stroke patients. *Am J Cardiol* 1994;74:381–384.

4. Rivera JC. Decompression sickness amongst divers: an analysis of 935 cases. *Mil Med* 1963;129:314–334.

5. Kidd DJ, Elliott DH. Clinical manifestations and treatment of decompression sickness in divers. In: Bennett PB, Elliott DH, eds. The Physiology and Medicine of Diving and Compressed Air Work. London: Baillere Tindall, 1969:464–490.

6. Desola AJ, San Pedro AG. Epidemiological study of 146 dysbaric diving accidents. In: Desola AJ, ed. Diving and Hyperbaric Medicine. Barcelona: Proceedings of the IX Congress of the European Undersea Biomedical Society, 1984.

7. Waggoner AD, Davila-Roman VG, Barzilai B, Perez JE. Contrast two-dimensional echocardiography provides clinical information not available with color flow imaging. *JDMS* 1992;8:2–13.

8. Griner PF, Mayewski RJ, Mushlin AI, Greenland P. Selection and interpretation of diagnostic tests and procedures: principles and applications. *Ann Intern Med* 1981;94:559–600.

9. Weathersby PK, Survanshi SS, Hays JR, MCallum ME. Statistically based decompression tables. III. Comparative risk using US Navy, British and Canadian standard air schedules. Medical Research Progress Report of the Naval Medical Research Institute. NMRI 86-50. Bethesda: Naval Medical Research Institute, 1986.

10. Behnke AR. A review of physiologic and clinical data pertaining to decompression sickness. Project X-443, Report No. 4. Bethesda, Naval Medical Research Institution, 1947.

11. Bruning JL, Kintz BL, eds. Computational Handbook of Statistics. 2nd ed. Glenview, Ill: Scott, Foresman, 1977:222–224.

12. Wilmshurst PT, Byrne JC, Webb-Peploe MM. Relation between interatrial shunts and decompression sickness in divers. *Lancet* 1989;2:1302–1306.

13. Hagen PT, Scholz DG, Edwards WD. Incidence and size of patent foramen ovale during the first 10 decades of life: an autopsy study of 965 normal hearts. *Mayo Clinic Proc* 1984;59:17–20.

14. Zhu W-X, Kandheria BK, Click RL, OH JK, Freeman WK, Seward JB, Tajik AJ. Patent foramen ovale detected by contrast transesophageal echo: a lack of association with systemic embolic events (abstr). *Circulation* 1991;84(suppl II):II–2757.